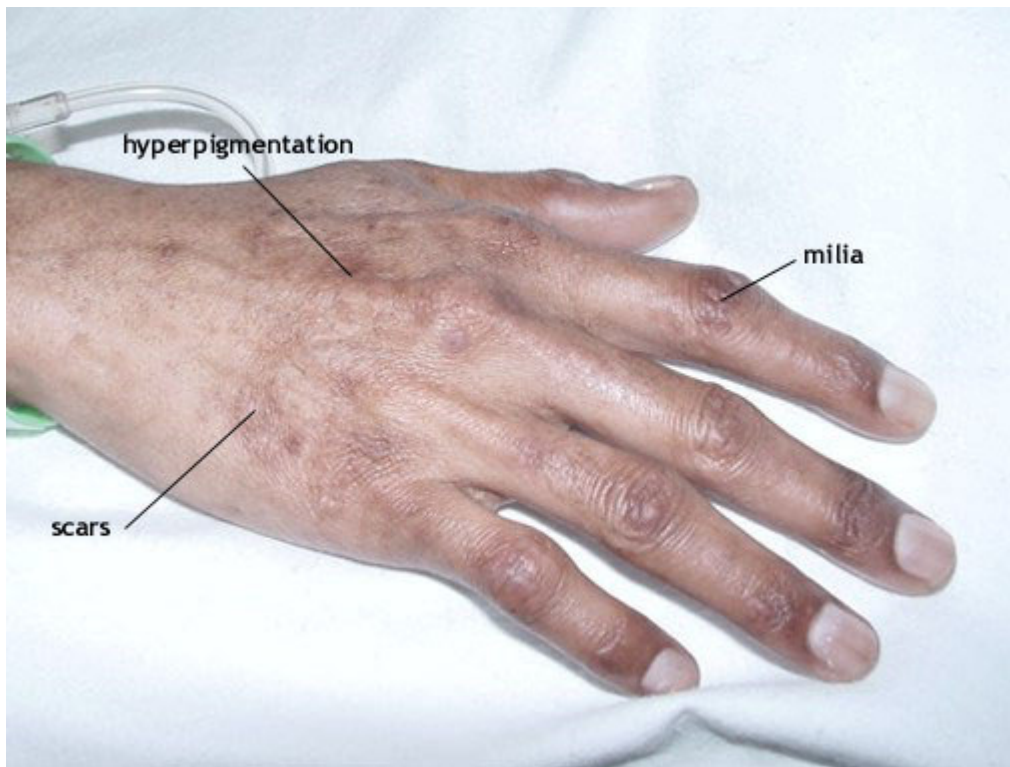


TYPICAL SKIN DISEASE IN PORPHYRIA CUTANEA TARDA AND VARIEGATE PORPHYRIA



Typical skin lesions of porphyria as seen in porphyria cutanea tarda (PCT) and variegate porphyria (VP). Acute lesions consist of blisters, erosions and scabs. These heal leaving areas of hyperpigmentation and hypopigmentation. Milia are pinpoint collections of a white, waxy substance just beneath the surface of the skin.